

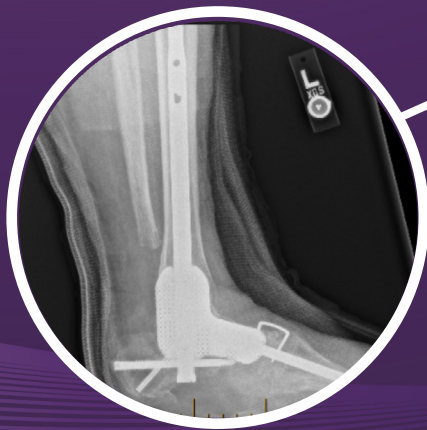CERAMENT® G
with Gentamicin

CASE REPORT

Medical Education Series

Diabetic Foot Osteomyelitis and Charcot Foot Reconstruction

Dr. Brian R. Benson, DPM, M.S., MPH, AACAS
*Fellowship Training Podiatric Surgeon
Beauregard Health System
DeRidder, Louisiana*



Diabetic Foot Osteomyelitis and Charcot Foot Reconstruction

PATIENT HISTORY

A 58 year old female with a background of diabetes and charcot foot, presented with a chronic wound on the plantar aspect of her foot. She previously had multiple debridement and local wound care. After multiple surgeries her wound remained infected. She was presented with two options for her wound - either to attempt limb salvage surgery or to opt for a below knee amputation. She decided to try limb salvage surgery first.

DIAGNOSIS

Diabetic Foot Osteomyelitis and Charcot Foot.

TREATMENT

- 1) First operation - Forefoot debridement. Post-operatively she was treated with Dalbavancin IV, however her wound remained infected.
- 2) Second operation: Midfoot gigli osteotomy with external fixation. External fixator was left in place for 6 weeks.
- 3) Third and fourth operation: Removal of external fixation and Tibio-Talo-Calcaneal arthrodesis was performed using a hindfoot nail, while the medial column was addressed by using a plate and screw construct.

During the post-op period, the patient developed surgical wound dehiscence, with exposed bone. Additional bone biopsies, once again, revealed presence of acute osteomyelitis. Patient was admitted to hospital, and underwent removal of her metal work with 6 weeks of IV antibiotics. At the conclusion of IV abx therapy, additional bone biopsies were negative for osteomyelitis.

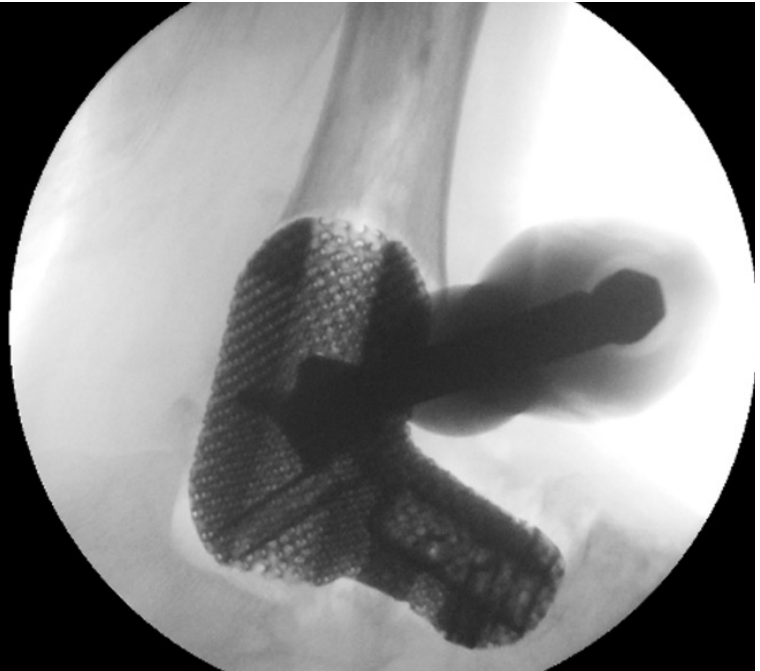
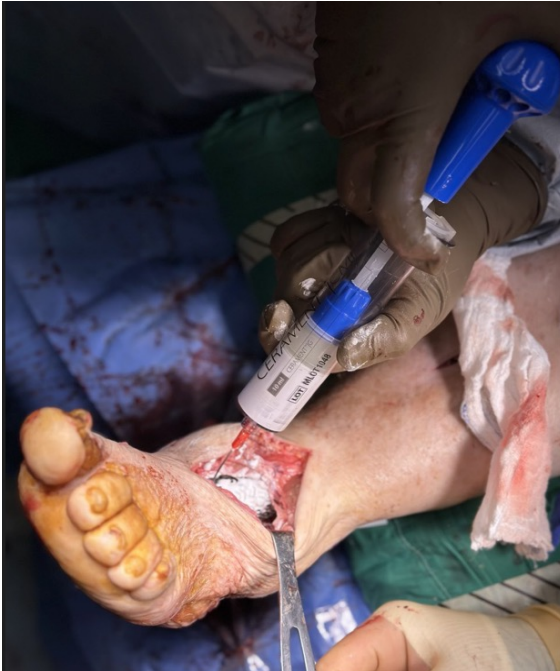- 4) Fifth and final operation with CERAMENT G: Implantation of custom 3D titanium, Tibio-Talo-Calcaneal hindfoot nail and medial column beam. CERAMENT G was injected into and around 3D implant, and used to fill osseous voids.

HARDWARE

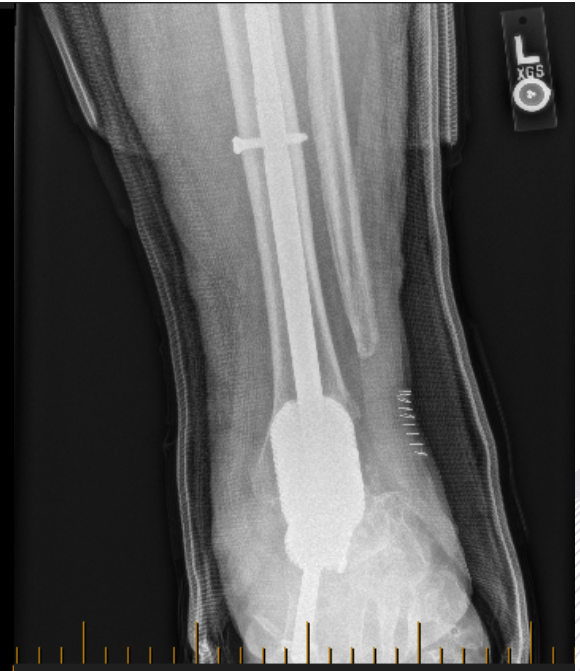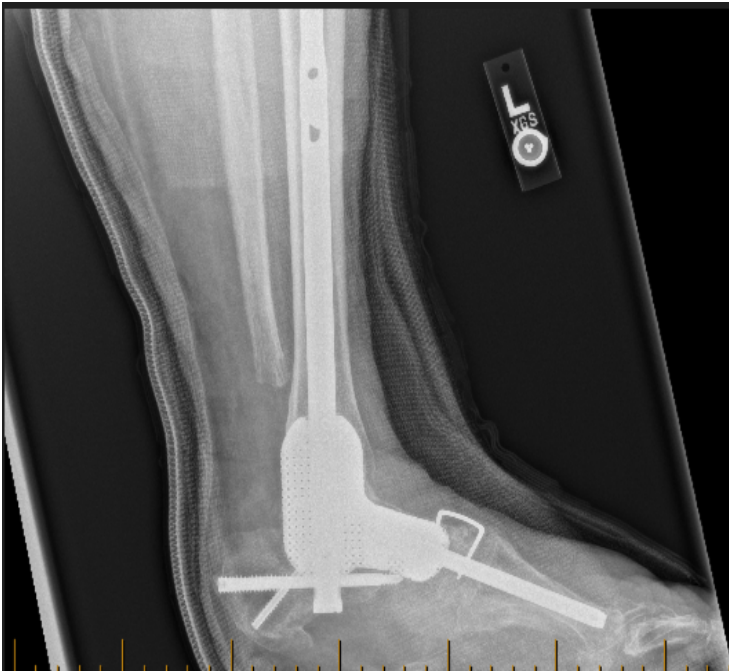Restor3d custom cage.

OUTCOME

After her procedure with CERAMENT G – she has had no further surgical intervention or systemic antibiotics. She is currently attending physiotherapy and ambulating with use of custom dynamic ankle foot orthoses.



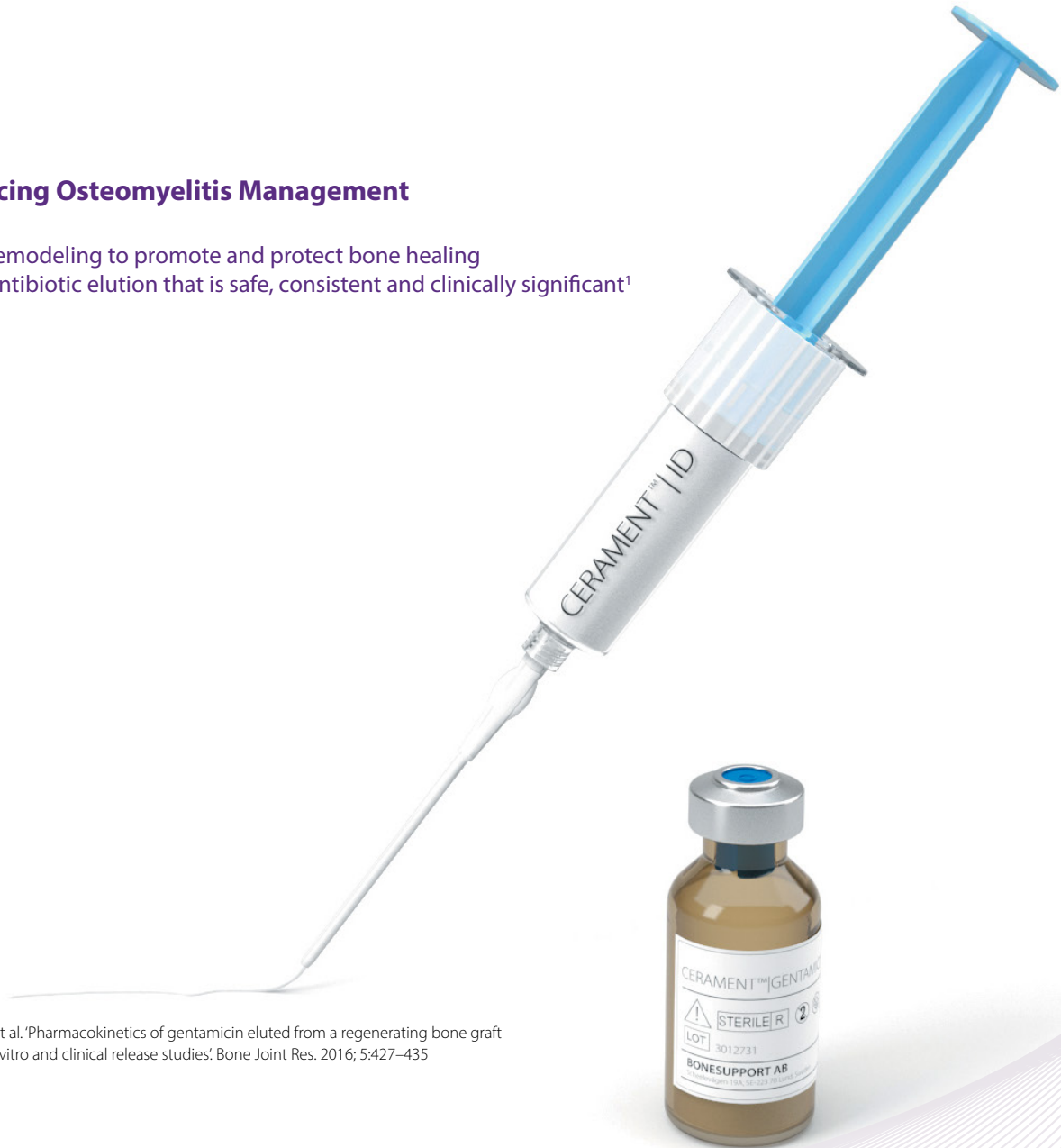Intra-op images of CERAMENT G injected around the custom cage (Restor3d).



6-month post-op images showing bony union and a stable construct.

Advancing Osteomyelitis Management

- Bone remodeling to promote and protect bone healing
- Local antibiotic elution that is safe, consistent and clinically significant¹



¹ Stravinskas et al. 'Pharmacokinetics of gentamicin eluted from a regenerating bone graft substitute - In vitro and clinical release studies'. Bone Joint Res. 2016; 5:427-435

TO ORDER

order@bonesupport.com



BONESUPPORT AB
Ideon Science Park,
Scheelevägen 19
SE-223 70 Lund, Sweden

BONESUPPORT, INC.,
117 Fourth Ave, Suite 202
Needham, MA 02494

T: +46 46 286 53 70
F: +46 46 286 53 71
E: info@bonesupport.com

T: +1.877.719.6718
E: us.sales@bonesupport.com
W: bonesupport.com



PR-01433-01 AU CA EU ROW US 01-2024