

# CERAMENT® G

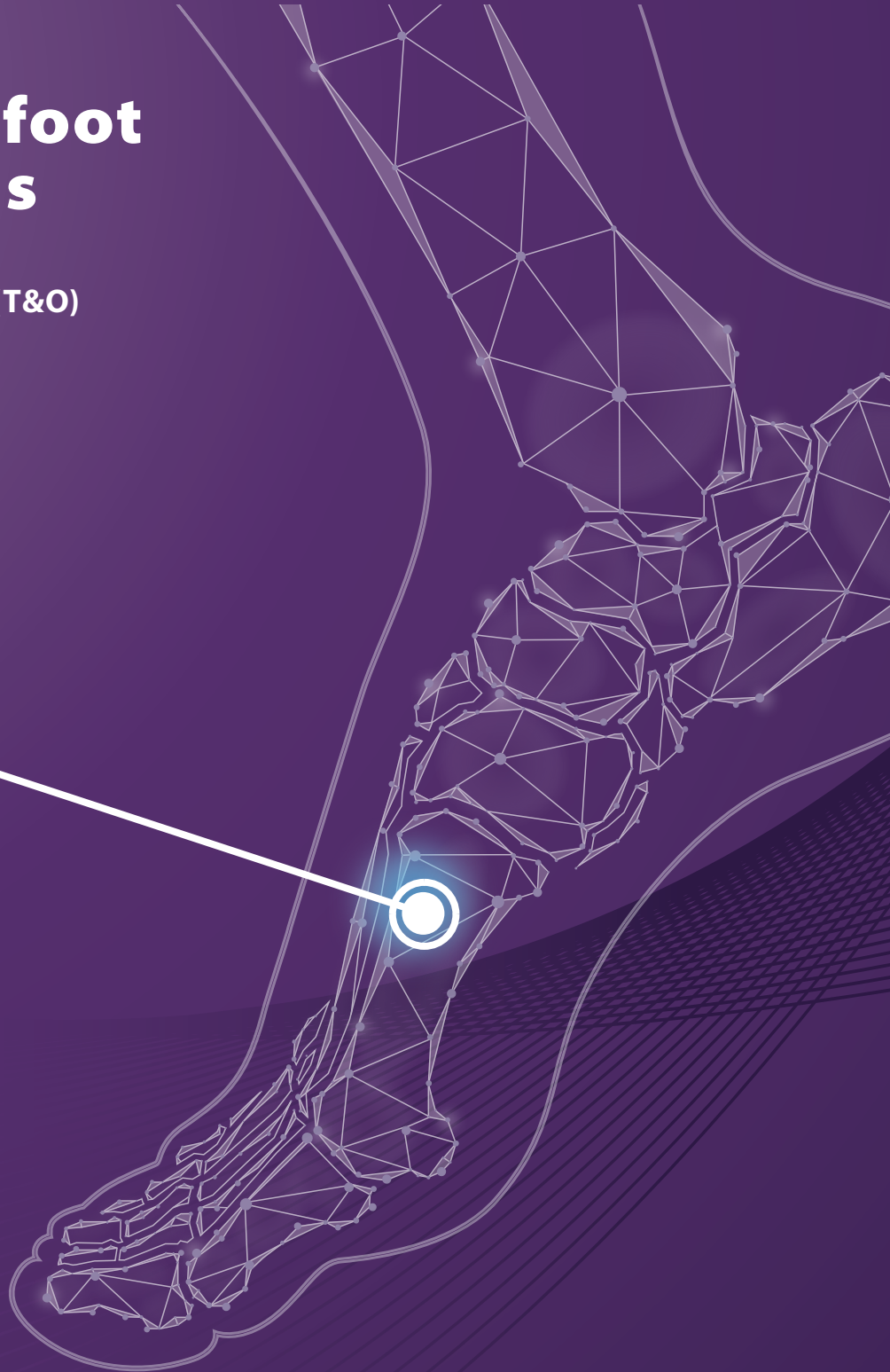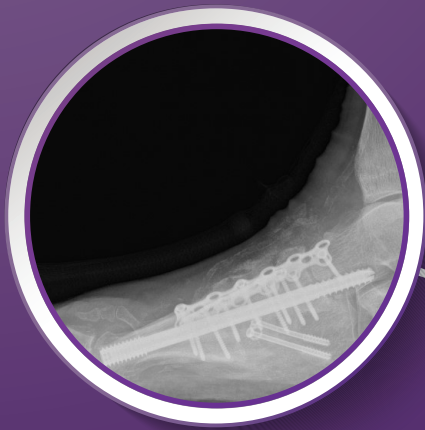
with Gentamicin

CASE REPORT

Medical Education Series

## Diabetic Midfoot Osteomyelitis

M. Tiruveedhula, MD, FRCS (T&O)  
*Essex, United Kingdom*



# Diabetic Midfoot Osteomyelitis

## PATIENT HISTORY

A 62 year old, poorly controlled diabetic presented with midfoot Charcot deformity. After Endocrine and vascular work-up, a single stage midfoot reconstruction was performed with Tendo-Achilles Lengthening and stabilisation of midfoot with internal fixation using beams and plates (Fig. 1 - 3).

## DIAGNOSIS

3 months after reconstruction, the patient presented with dehiscence of medial surgical wound with radiological evidence of midfoot osteomyelitis. A 2-staged reconstruction was planned.

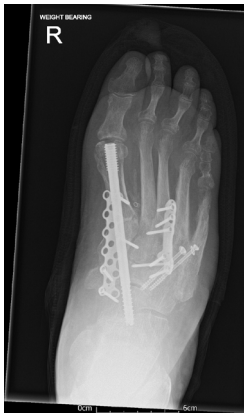

Figure 1  
Post-op - AP radiograph

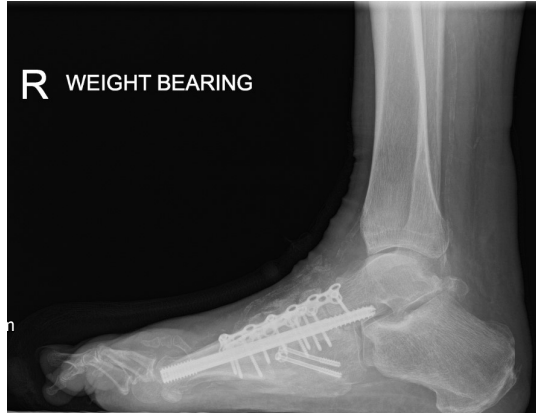


Figure 2  
Post-op - Lateral radiograph

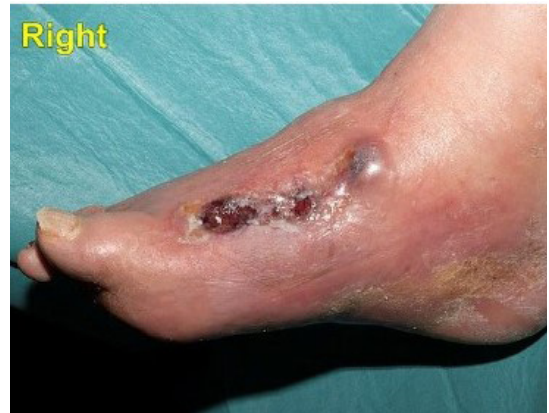

Figure 3  
Post-op - right foot infection medial wound

## TREATMENT

- In the first stage, removal of all the metalwork, debridement of infected soft tissues and areas of osteomyelitis was carried out, deep samples were taken and the dead space filled with CERAMENT G. Temporary 2.8mm wires were used to stabilise the midfoot (Fig. 4).
- Microbiology reported *Staphylococcus aureus*, so the patient was treated with culture specific antibiotics, intravenous for 2 weeks followed by 4 weeks of oral antibiotics, while the foot was supported in a plaster cast with wound checks every 2 weeks.
- In the second stage, surgery is ideally planned when all the surgical wounds have healed well and blood inflammatory markers returned to normal. The second stage would have involved assessment of joint surfaces for signs of infection with deep samples, and using CERAMENT G to manage dead space before stabilisation with internal fixation using the principles of superconstruct. However, in this patient, second stage surgery could not be performed due to the Covid-19 pandemic and the patient was monitored clinically and radiologically for bony stability (Fig. 5 & Fig. 6).

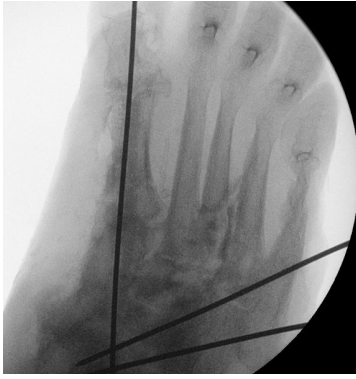

Figure 4  
Intra-op first stage revision with  
CERAMENT® G

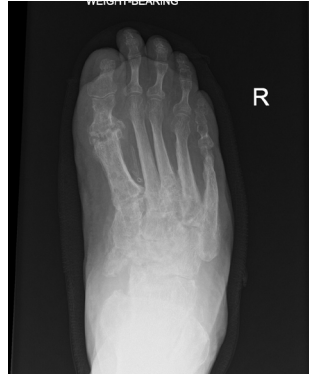

Figure 5  
6 weeks post first stage revision -  
AP radiograph

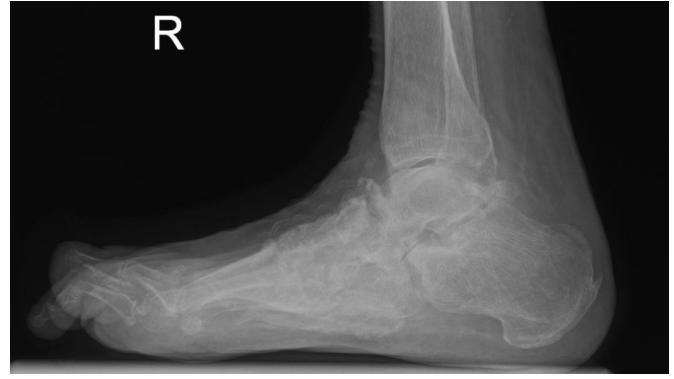

Figure 6  
6 weeks post first stage revision - Lateral radiograph

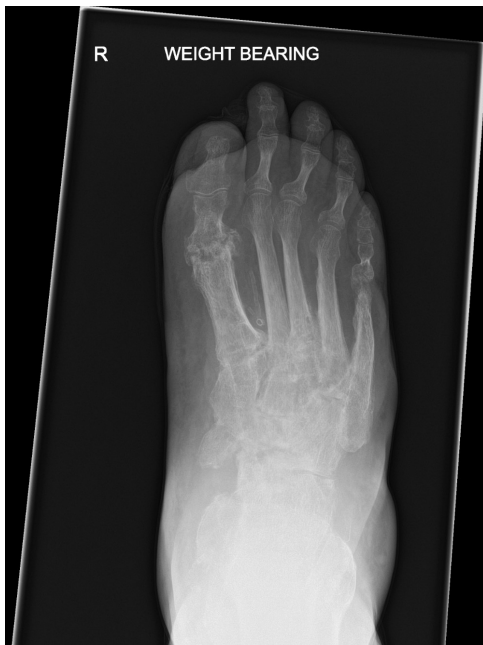

Figure 7  
5 months post first stage revision - AP radiograph

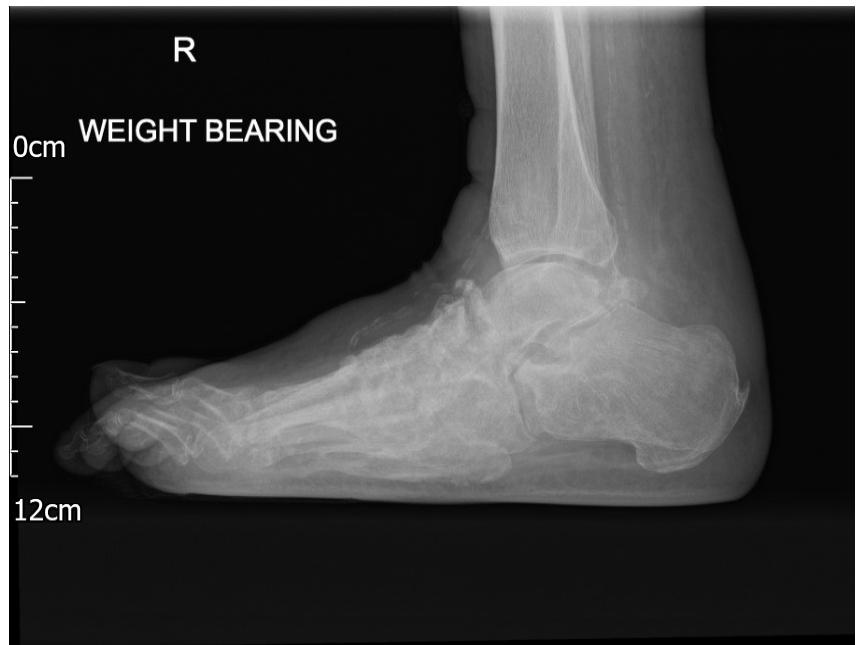

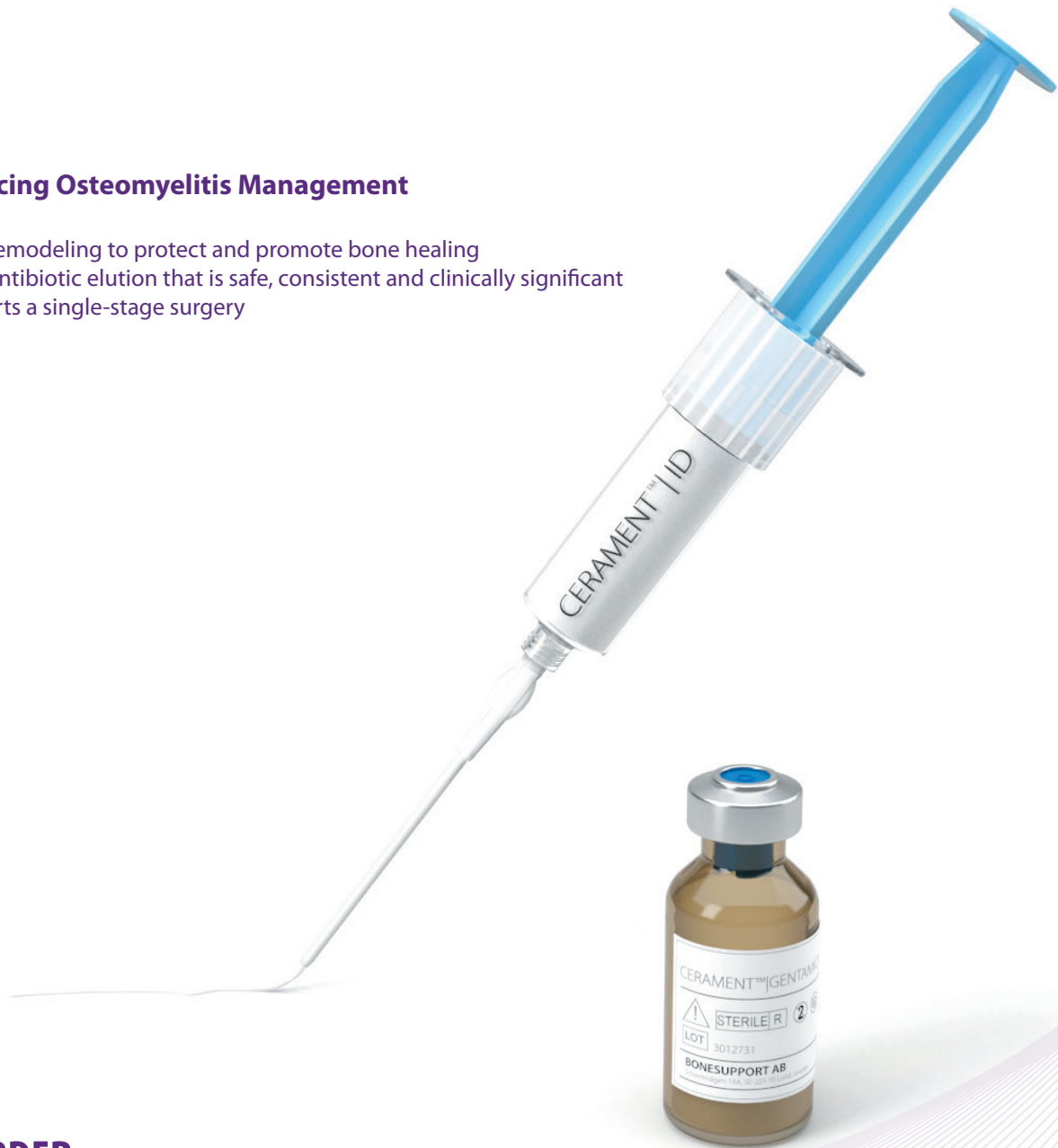Figure 8  
5 months post first stage revision - Lateral radiograph

## OUTCOME

- Clinical and radiological assessment revealed a stable foot with completely healed surgical wounds. The patient's weight bearing status progressed from non-weight bearing through partial weight bearing in a removable boot, progressing on to full weight bearing.
- The weight-bearing radiographs remained stable and the final radiographs (5 months post-first stage procedure) showed a stable midfoot (Fig. 7 & Fig. 8).
- At 12-m post-first stage, the foot remained stable, infection-free, and the patient was walking comfortably in a customized orthosis (virtual video consult).
- CERAMENT G in this case helped to eradicate infection, fill the dead space, and provided stability to the midfoot.

## Advancing Osteomyelitis Management

- Bone remodeling to protect and promote bone healing
- Local antibiotic elution that is safe, consistent and clinically significant
- Supports a single-stage surgery



**TO ORDER**

**ORDER@BONESUPPORT.COM**



BONESUPPORT AB  
Ideon Science Park,  
Scheelevägen 19  
SE-223 70 Lund, Sweden

T: +46 46 286 53 70  
F: +46 46 286 53 71  
E: [info@bonesupport.com](mailto:info@bonesupport.com)  
W: [bonesupport.com](http://bonesupport.com)



PR 01229-01 en AU CA EU ROW 03-2022