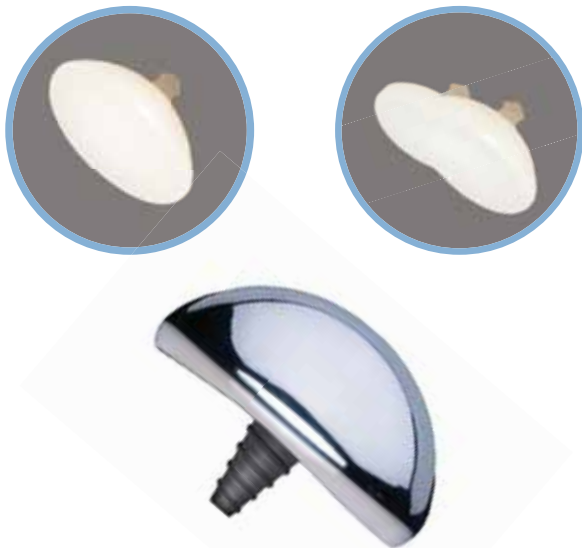

Non-Lateralizing Total Shoulder

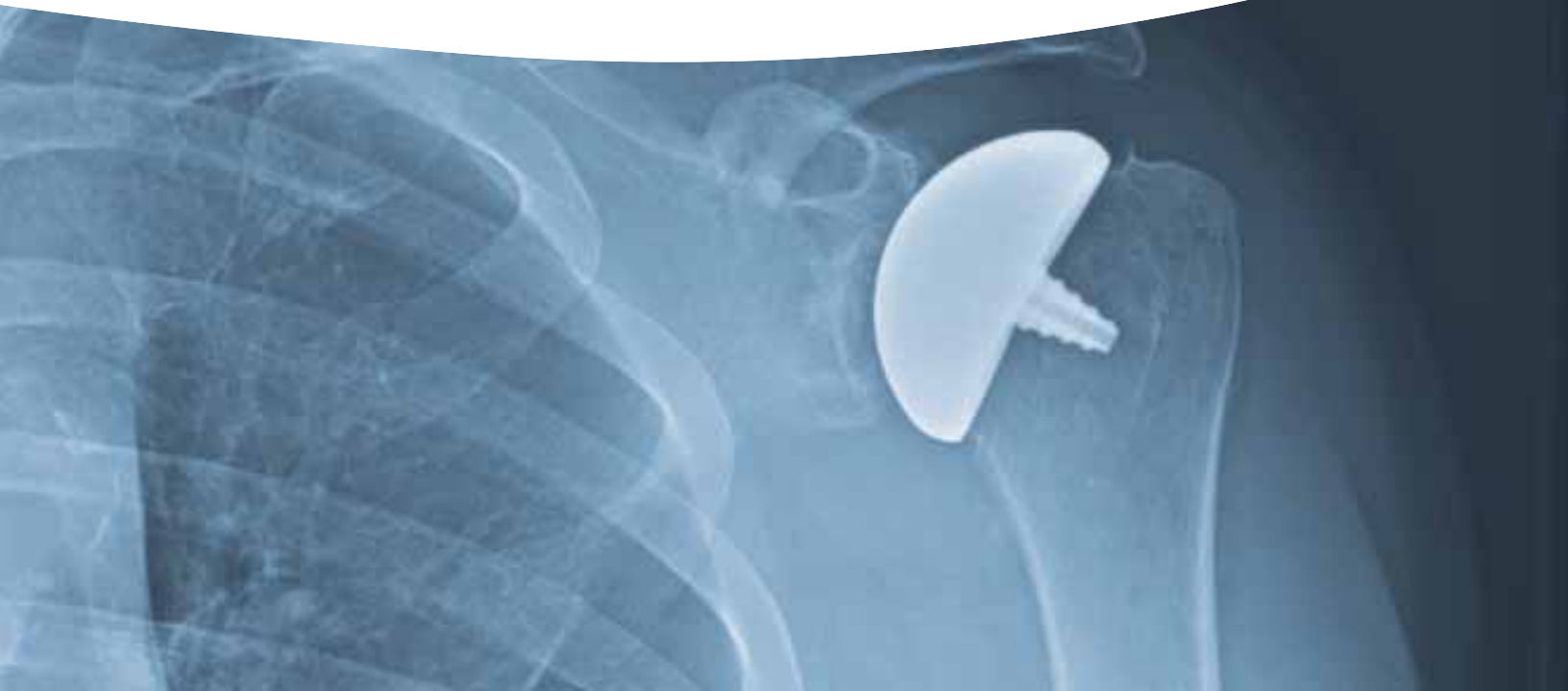Featuring an Inlay Glenoid with a Canal Sparing Humeral Head



**HEMICAP[®] OVO IMPLANT
WITH SINGLE & DOUBLE ANATOMIC
INLAY GLENOID IMPLANT**

"We found that alteration of the humeral head geometry may greatly influence the contact pressure and stress distribution in the glenoid. In order to reproduce the behavior of an intact shoulder, humeral arthroplasties should reproduce the anatomy of the intact shoulder head."

Benefits of an anatomical reconstruction of the humeral head during shoulder arthroplasty: a finite element analysis; Büchler, P. et al.; Clinical Biomechanics, 2004, Volume 19, Issue 1, 16 - 23



INLAY GLENOID ARTHROPLASTY

36 MONTH SHOULDER CASE STUDY

✓ DEMOGRAPHICS & DIAGNOSIS

Age: 53

Gender: Female

Occupation: Casino Dealer

Diagnosis: Left GH Osteoarthritis

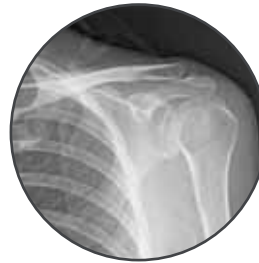✓ PRIMARY COMPLAINT

Spontaneous onset of pain, waking her up at night; 9 months of difficulty raising arm above shoulder level.

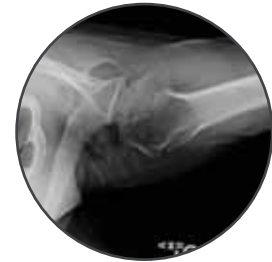Anti-inflammatories yielded little to no improvement.

✓ PRE-OPERATIVE EXAMINATION

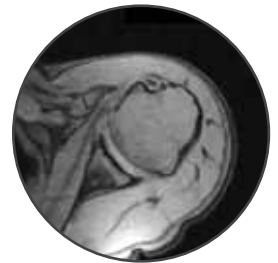
- Forward Flexion: 160
- Abduction: 90
- External Rotation: 50
- Crepitus with motion
- Glenoid Walsh Classification Type 1A
- Constant Score: 53
- X-Rays indicate severe OA of the glenohumeral joint with goatbeard osteophyte and intact RTC



Pre-operative AP view with GH Osteoarthritis.



Pre-operative Axillary view with glenoid stage Walsh 1A.

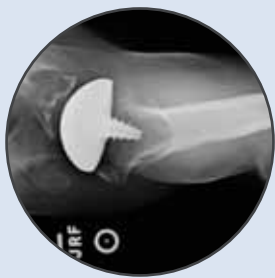

Pre-operative axillary MRI with Walsh Type 1A Glenoid showing severe GH OA and head flattening.

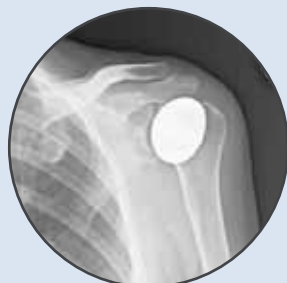TREATMENT

Left total shoulder arthroplasty, delto-pectoral approach, osteophyte removal, open biceps tenodesis, off-axis inlay glenoid replacement and anatomic humeral head resurfacing.

Implants: Arthrosurface non-spherical HemiCAP[®] OVO & Inlay Glenoid System.



Post-Operative axillary view showing humeral head centered in glenoid vault.



Post-Operative AP with well fixed implants.

✓ POST-OPERATIVE EXAMINATION

2 Months Post-Op:

- Forward Flexion: 160

18 Months Post-Op:

- Forward Flexion: 160
- Abduction: 160
- External Rotation: 70
- Internal Rotation: L1
- No crepitus with motion
- Constant Score: 96

✓ FOLLOW-UP / CONCLUSION

Patient returned to work full time 77 days after surgery.

At 3 Year follow up patient reported:

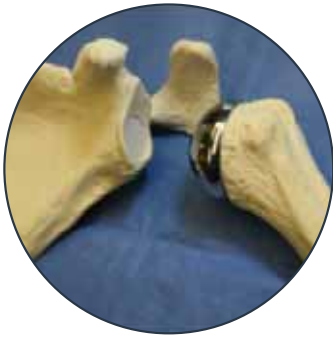- Excellent patient satisfaction
- Patient would have same surgery again
- Would recommend to friends & family

Design Rationale

Anatomic Glenoid

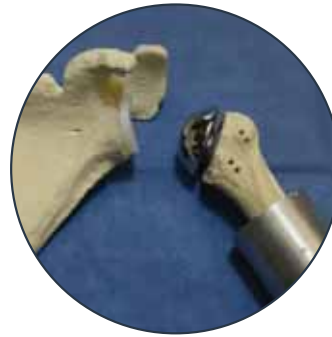Inlay vs. Onlay Survivorship Comparison:

Presented at ORS Meeting 2015, Las Vegas, NV



Inlay Glenoid & HemiCAP OVO Resurfacing

VERSUS



Onlay Glenoid & Stemmed Humeral Replacement

Specimen	1	2	3	4	5	6	7	8
Onlay	875	1372	1463	772	1838	n/a**	814	749
Inlay	4000*	4000*	4000*	4000*	4000*	4000*	4000*	4000*

*Glenoid Fatigue Testing Results for 8 Specimens; Data Source: Gagliano et al., ORS, 2015

Conclusion:

The inlay implant resisted visible loosening in all fatigue testing of 4000 cycles, however, all onlays showed loosening in under 2000 cycles.

The change in location of pressure during eccentric loading to a more central area provided better stability to the inlay because the pressure was diverted to the native tissue on the glenoid edge.

Anatomic Humerus

The Humeral Head is NOT a Sphere:




Figure 3: 50 Years of Evidence Showing Non-Spherical Humeral Head Geometry

*Ref: <http://www.arthrosurface.com/brochure/shoulder-clinical-monograph-humeral-head-sphere/>

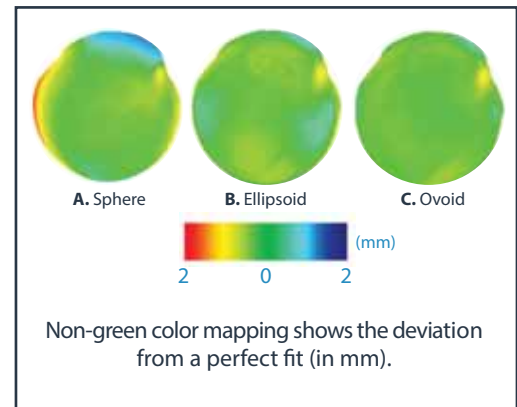


Figure 4: Topology of the Humeral Head Articular Surface: Ovoid Shape Shows 3x Better Match than Spherical Geometry

Conclusion:

The patient specific design concept was supported by Hammond et al. who showed that the center of rotation was more closely restored with inlay arthroplasty than with stemmed hemiarthroplasty. This resulted in less eccentric loading and potentially better functioning for the patient as the biomechanics of the joint and the moment arms of the rotator cuff and deltoid more closely resemble the intact condition. *Hammond et al. (PMID: 22218384)*

INLAY GLENOID ARTHROPLASTY

24 MONTH SHOULDER CASE STUDY

✓ DEMOGRAPHICS & DIAGNOSIS

Age: 57

Gender: Male

Occupation: Field Foreman

Diagnosis: Right GH Osteoarthritis

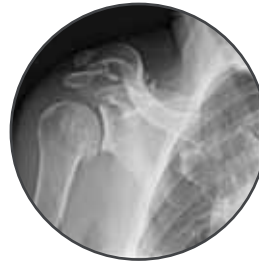✓ PRIMARY COMPLAINT

Right Shoulder pain which worsened over the last 5 years while working as a field foreman.

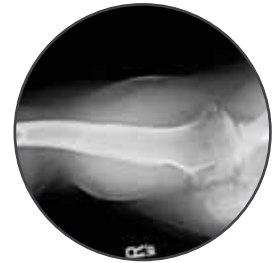Conservative treatments, including steroid injections failed.

✓ PRE-OPERATIVE EXAMINATION

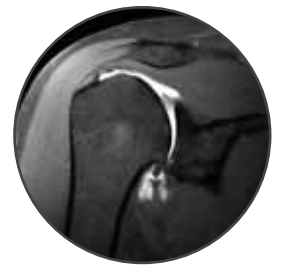- Active Forward Flexion: 150
- External Rotation: 50
- Internal Rotation: L5 with pain
- Strength: 4/5
- X-Rays indicate subchondral cysts in glenoid, humeral head acromial spurs and severe DJD.



Pre-operative AP view with GH Osteoarthritis.



Pre-operative axillary view with glenoid stage Walsh 1A.

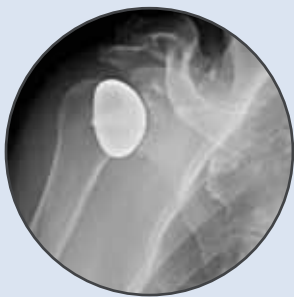

Pre-operative MRI with Walsh Type 1A Glenoid showing severe GH OA and head flattening.

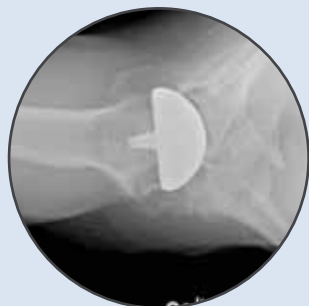TREATMENT

Right Total Shoulder Arthroplasty and Biceps Tenodesis.

Implants: Arthrosurface non-spherical HemiCAP[®] OVO & Inlay Glenoid Systems.



Post-Operative AP with well fixed implants.



24 Month Post-Operative axillary view showing humeral head centered in glenoid vault.

✓ POST-OPERATIVE EXAMINATION

1 Months Post-Op:

- Active Forward Flexion: 175
- External Rotation: 50
- Internal Rotation: L5
- Strength: 4/5

6 Months Post-Op:

- Active Forward Flexion: 160
- External Rotation: 80
- Internal Rotation: T7
- Strength: 5/5

24 Months Post-Op:

- Active Forward Flexion: 170
- External Rotation: 75
- Internal Rotation: L1
- Strength: 5/5
- X-Rays indicate a well maintained shoulder replacement with no bony abnormalities

✓ FOLLOW-UP / CONCLUSION

Patient returned to work full time 36 days after surgery.

- Excellent patient satisfaction
- Patient would undergo same surgery again
- Would recommend to friends & family

INLAY GLENOID ARTHROPLASTY

48 MONTH SHOULDER CASE STUDY

✓ DEMOGRAPHICS & DIAGNOSIS

Age: 52

Gender: Male

Occupation: Technician at Industrial Gas Company
and Body Builder

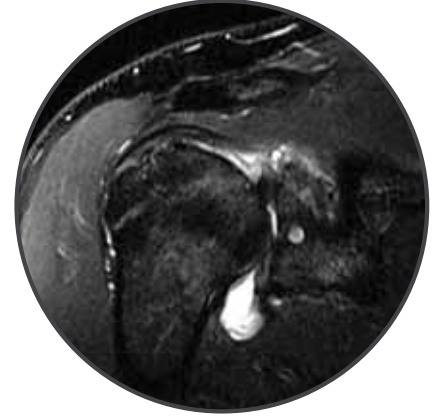Diagnosis: Right GH Osteoarthritis

✓ PRIMARY COMPLAINT

Right Shoulder Pain for past 5 years, which he attributes to overuse

✓ PRE-OPERATIVE EXAMINATION

- Active Forward Flexion: 160
- Active Abduction: 140
- External Rotation: 85
- Internal Rotation hip pocket
- Strength: 4/5
- X-Rays indicate Glenohumeral arthritis, labrum tear, RTC tendonitis

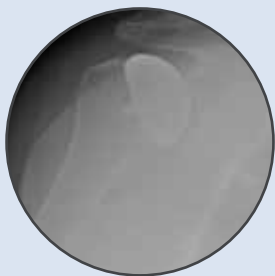

Pre-Operative MRI indicates DJD of Glenohumeral joint.

TREATMENT

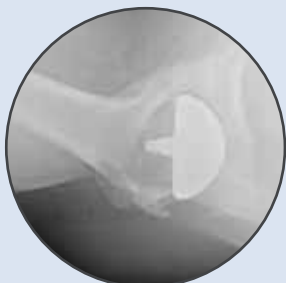Right Total Shoulder Arthroplasty and biceps tenodesis.

Implants: Arthrosurface non-spherical HemiCAP[®] OVO & Inlay Glenoid Systems.



Post-Operative AP with well fixed implants.

Post-Operative axillary view showing humeral head centered in glenoid vault.



✓ POST-OPERATIVE EXAMINATION

3 Month Post-Op:

- Active Forward Flexion: 155
- Active Abduction: 130
- External Rotation: 40
- Internal Rotation: back pocket
- Strength: 5/5

4 Years Post-Op:

- Active Forward Flexion: 150
- External Rotation: 90
- Internal Rotation: Lumbosacral jct
- Strength: 5/5

✓ PATIENT SATISFACTION

Patient returned to work full time 87 days after surgery.

- Outcome Rating: Excellent
- Patient is satisfied with the current state of his shoulder
- Would undergo the procedure again & recommend to friends & family

Comparison of Canal Sparing versus Stemmed Modular TSR

GLENOID	Arthrosurface Anatomic	Traditional Stemmed Modular	Short Reference
Implant Matches Native Glenoid Surface	YES	NO	Braman et al. PMID 16705689
Preserves Peripheral Glenoid Bone	YES	NO	Gunther et al. PMID 22173268
Prevents Joint Lateralization	YES	NO	Gunther et al. PMID 22173268
Minimizes Rocking Horse Effect	YES	NO	Gagliano et al. ORS 2015
Avoids Bone Grafting for Type C Glenoid	YES	NO	Davis et al. PMID 26908172
HUMERUS	Arthrosurface Anatomic	Traditional Stemmed Modular	Short Reference
Maintains Anatomic Geometry Without Altering Height, Version, Inclination Angle or Joint Volume	YES	NO	Büchler et al. PMID 14659925
Minimizes Blood Loss	YES	NO	Berth et al. PMID 23138538
Preserves Bone	YES	NO	Levy et al. PMID 11284568
Unique Ovoid Shape Minimizes Overstuffing	YES	NO	Harryman et al. PMID 7713972
Reduces Risk of Periprosthetic Fx & Allows Uncomplicated Conversion to Primary Stemmed TSR	YES	NO	Levy et al. PMID 15111895
Minimizes Eccentric Loading on the Glenoid	YES	NO	Hammond et al. PMID 22218384



For more information, visit our website:

www.arthrosurface.com

28 Forge Parkway • Franklin, MA 02038

1 508 520 3003

fax: 1 508 528 3785

This product is covered by one or more of U.S. Patent Nos. 6,520,964; 6,610,067; 6,679,917 and other patents pending. HemiCAP® is a trademark of Arthrosurface, Inc. U.S. © 2015 Printed in U.S.A.

This pamphlet and information is intended for markets where regulatory approval has been granted.

Patients provided written consent for publication of these case studies

For additional product information, including indications, contraindications, warnings, precautions and potential adverse effects, please visit www.arthrosurface.com. The HemiCAP® family of devices is cleared by FDA and via international CE Mark

PN 0025-0014 REV B

© 2017 Arthrosurface, Inc. All rights reserved.